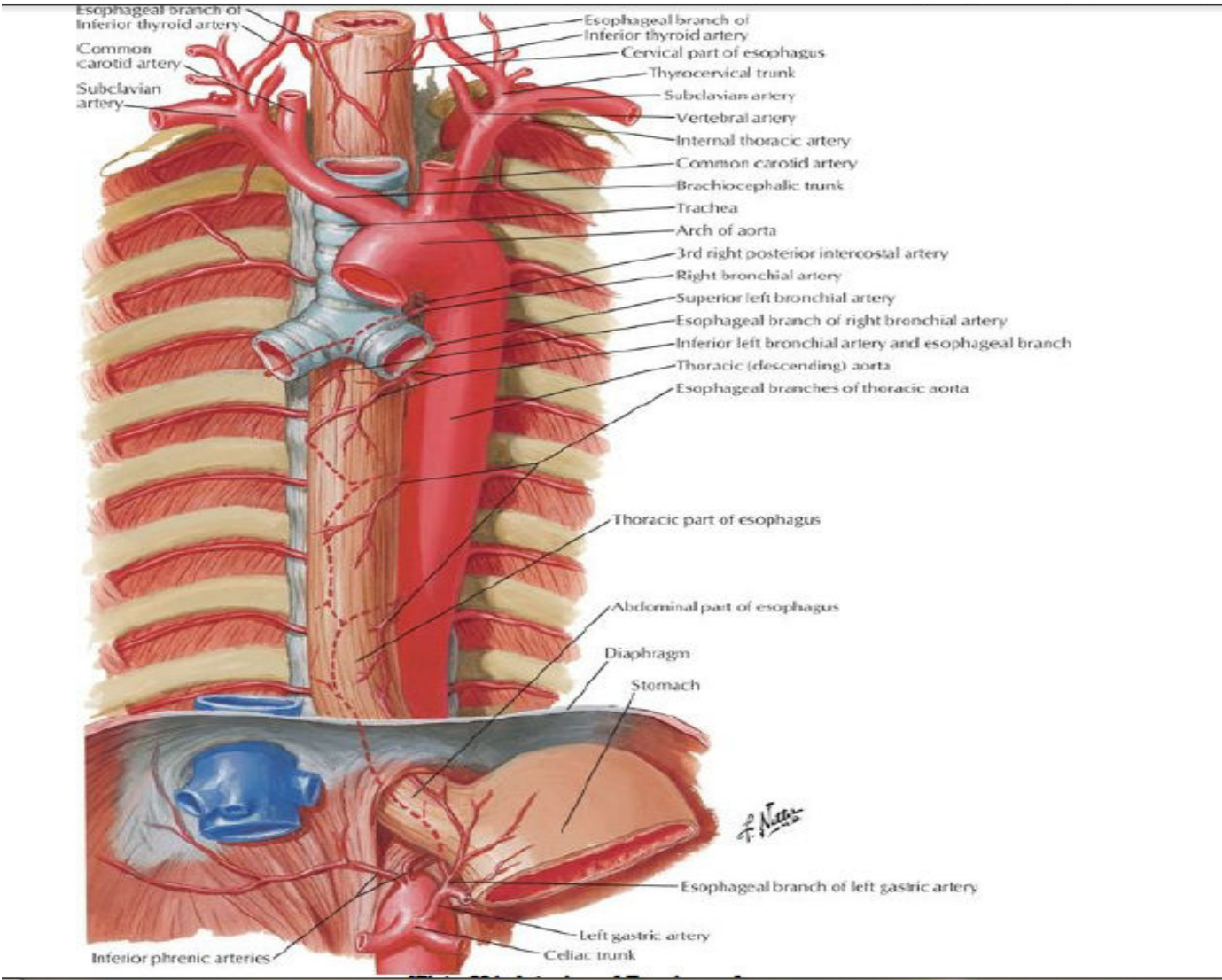
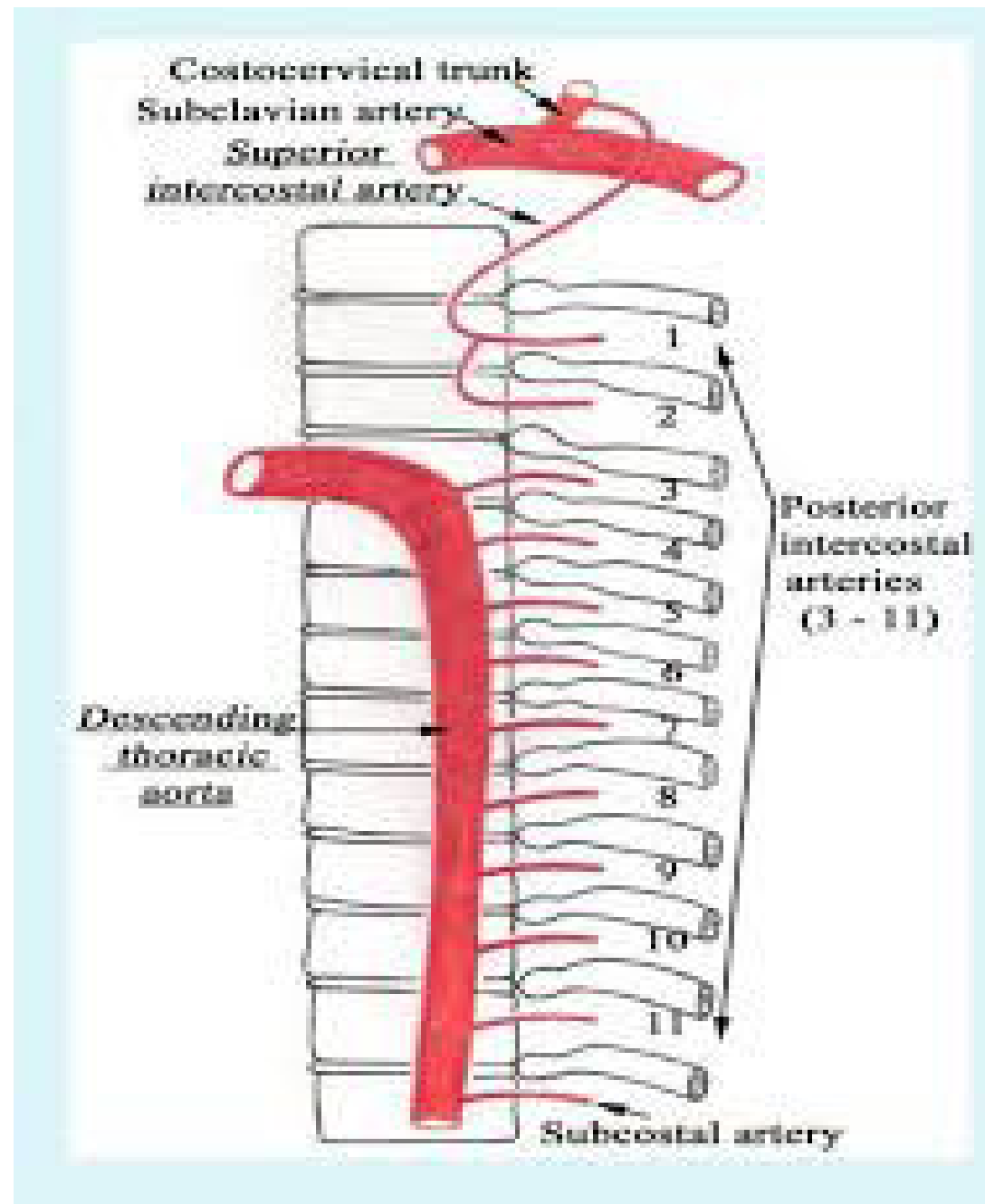


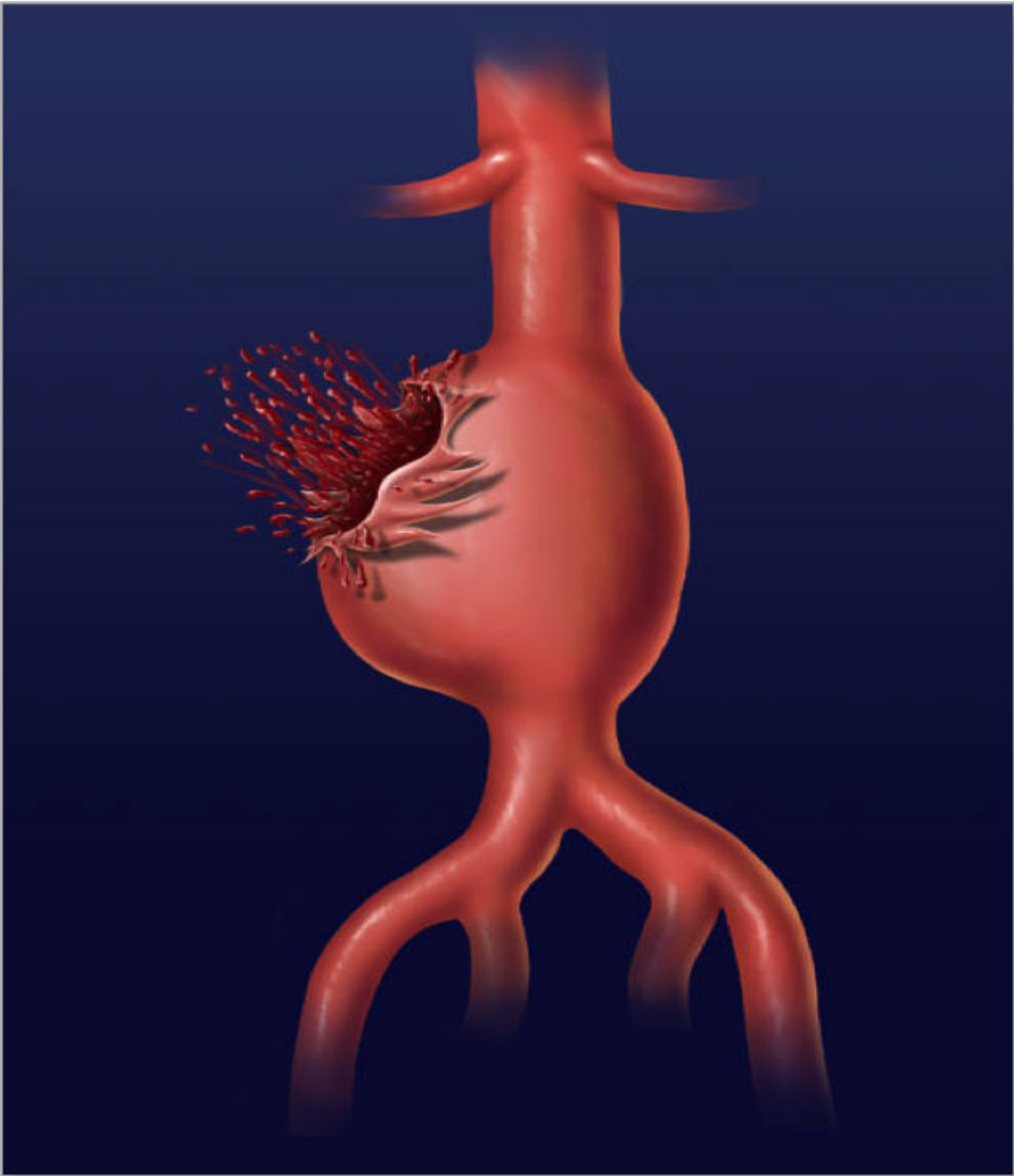
# BLOOD SUPPLY OF THE THORAX AND THE ABDOMEN

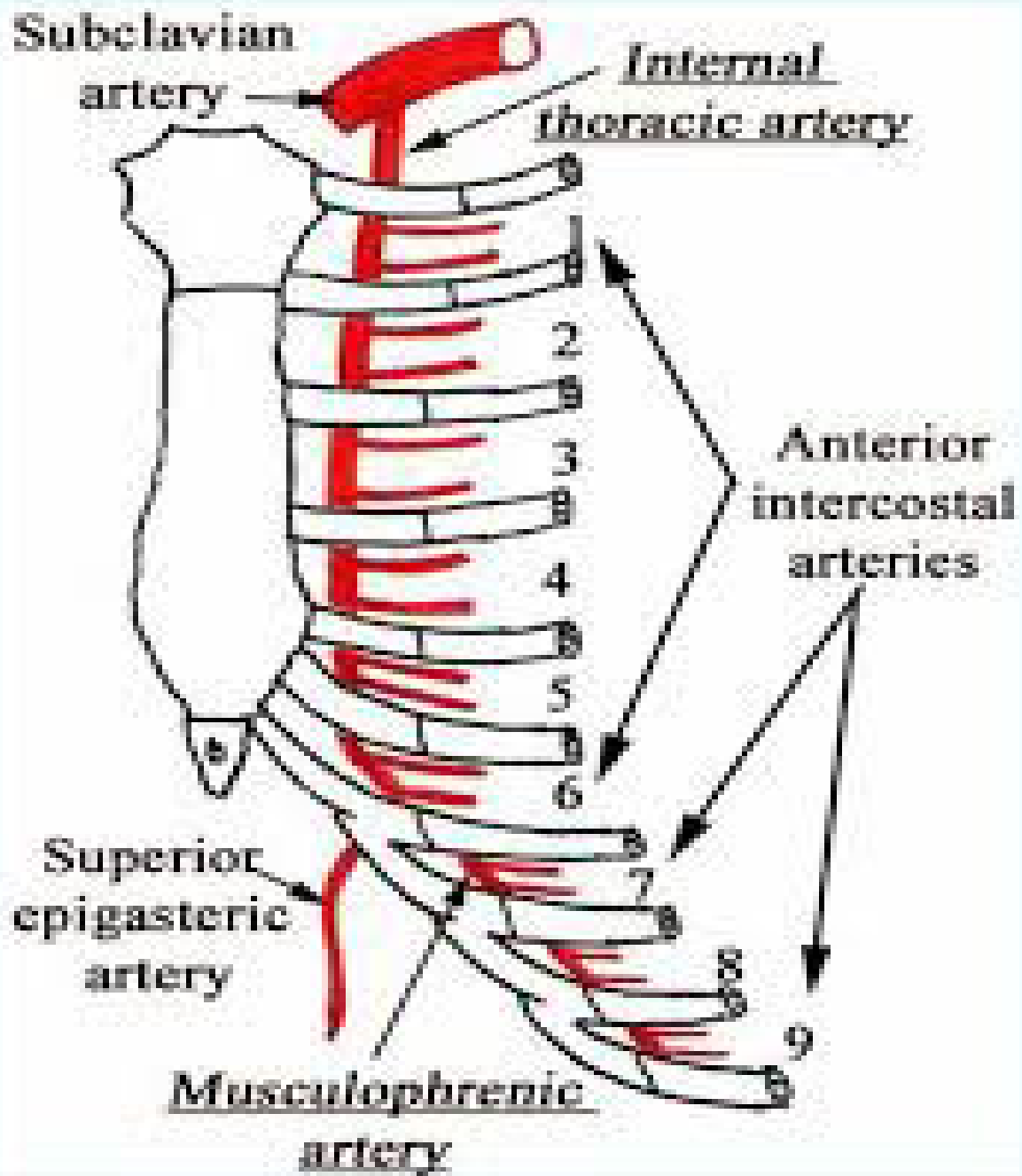
Anatomy department  
Beni-suef university

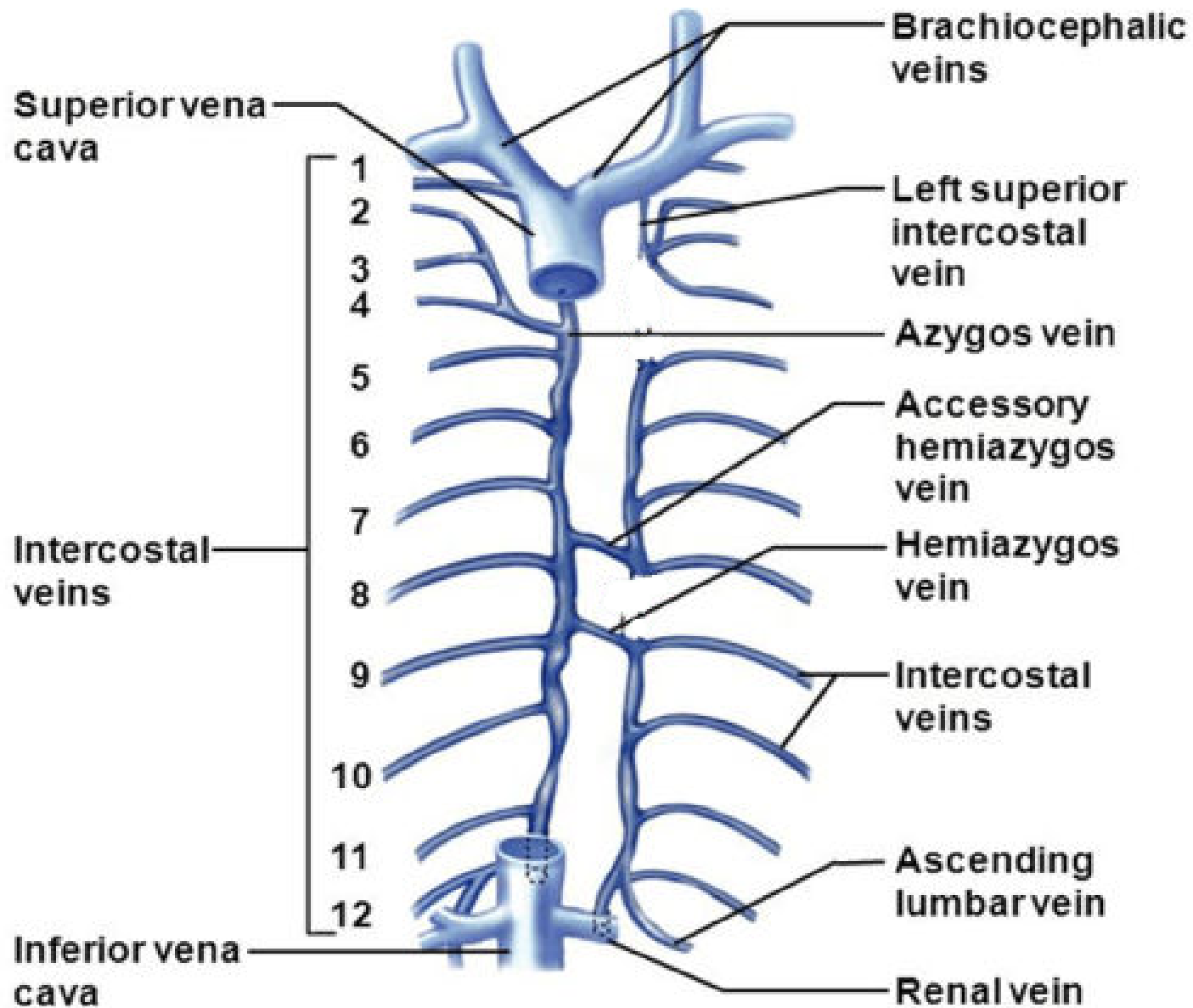
# THORACIC AORTA

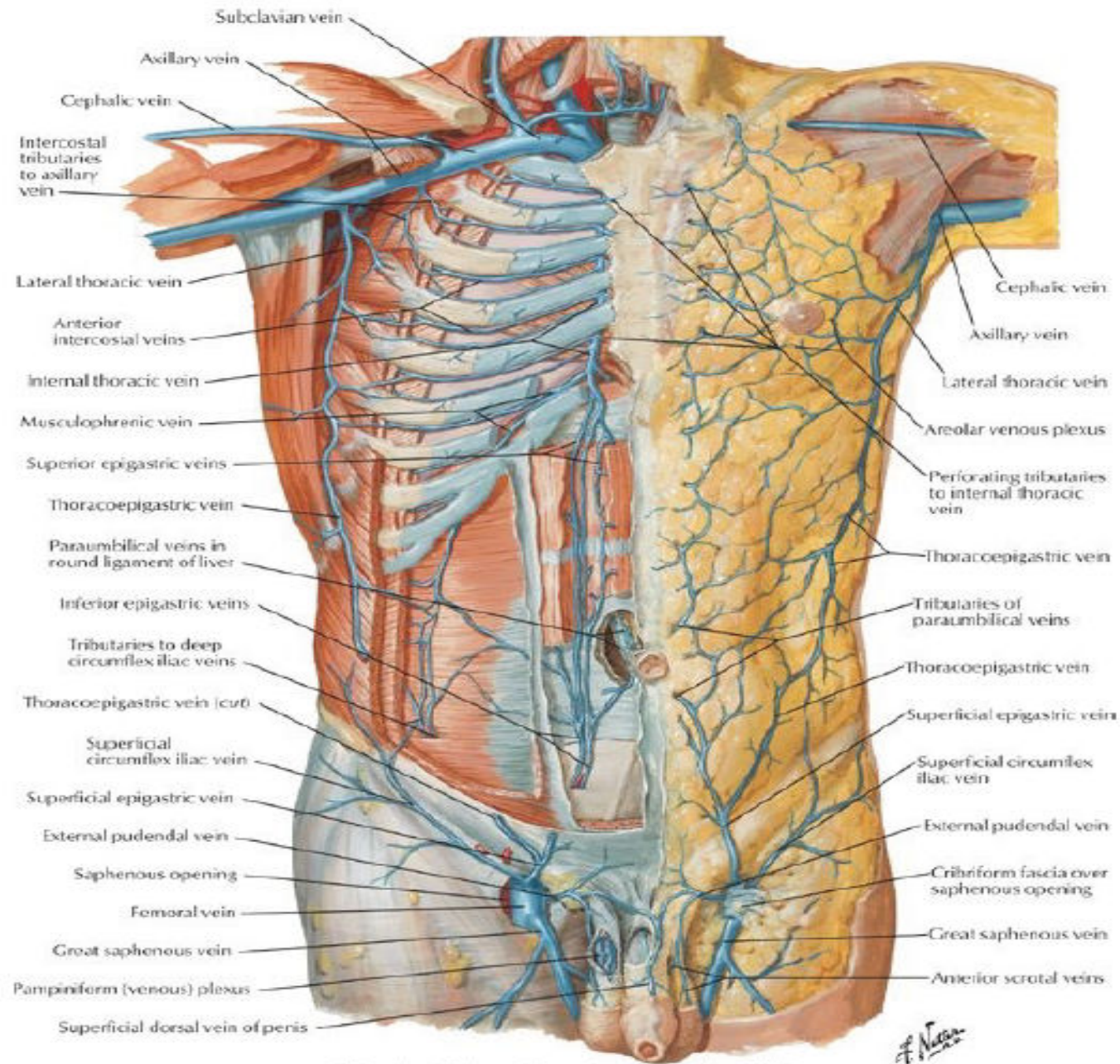


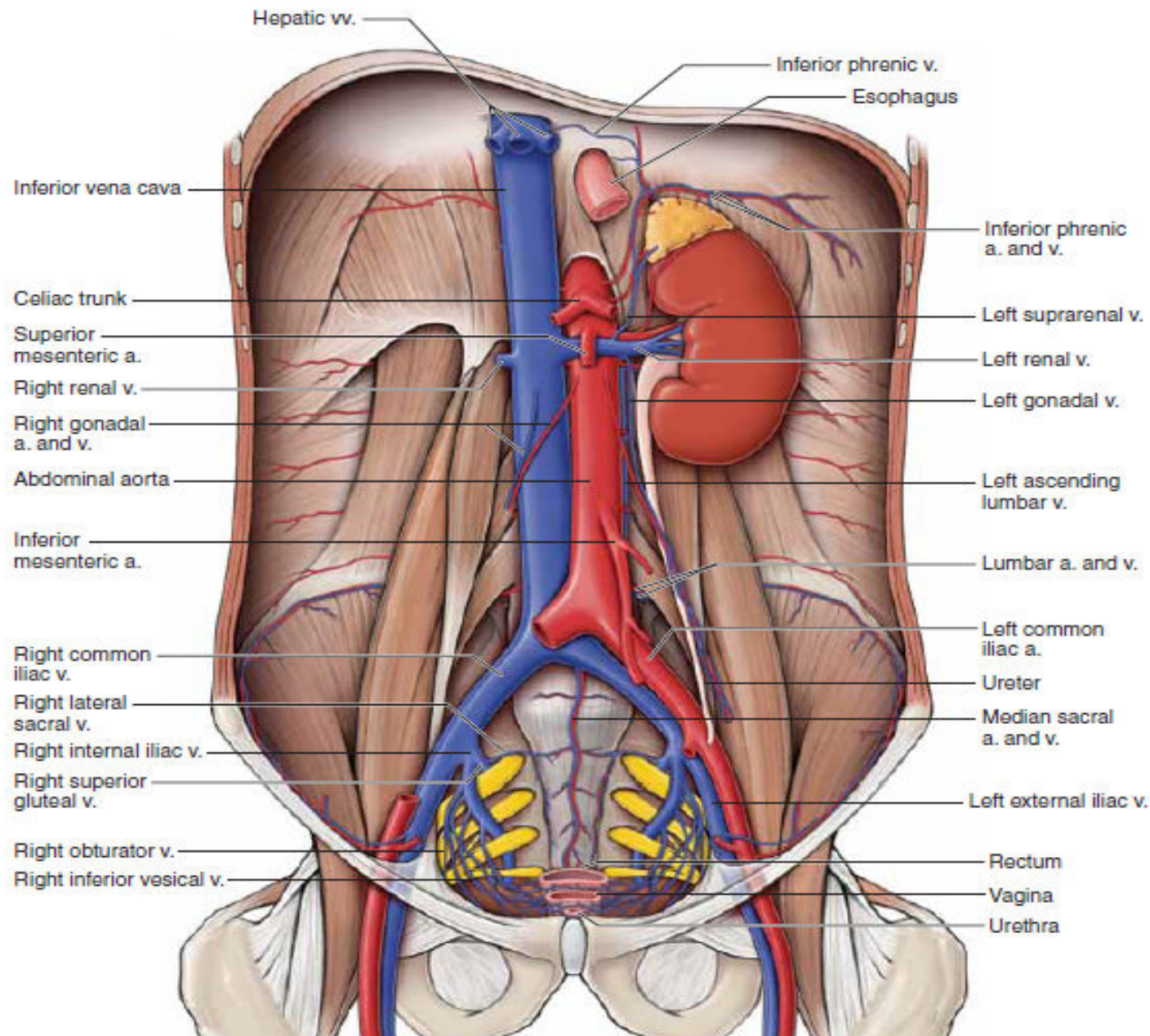




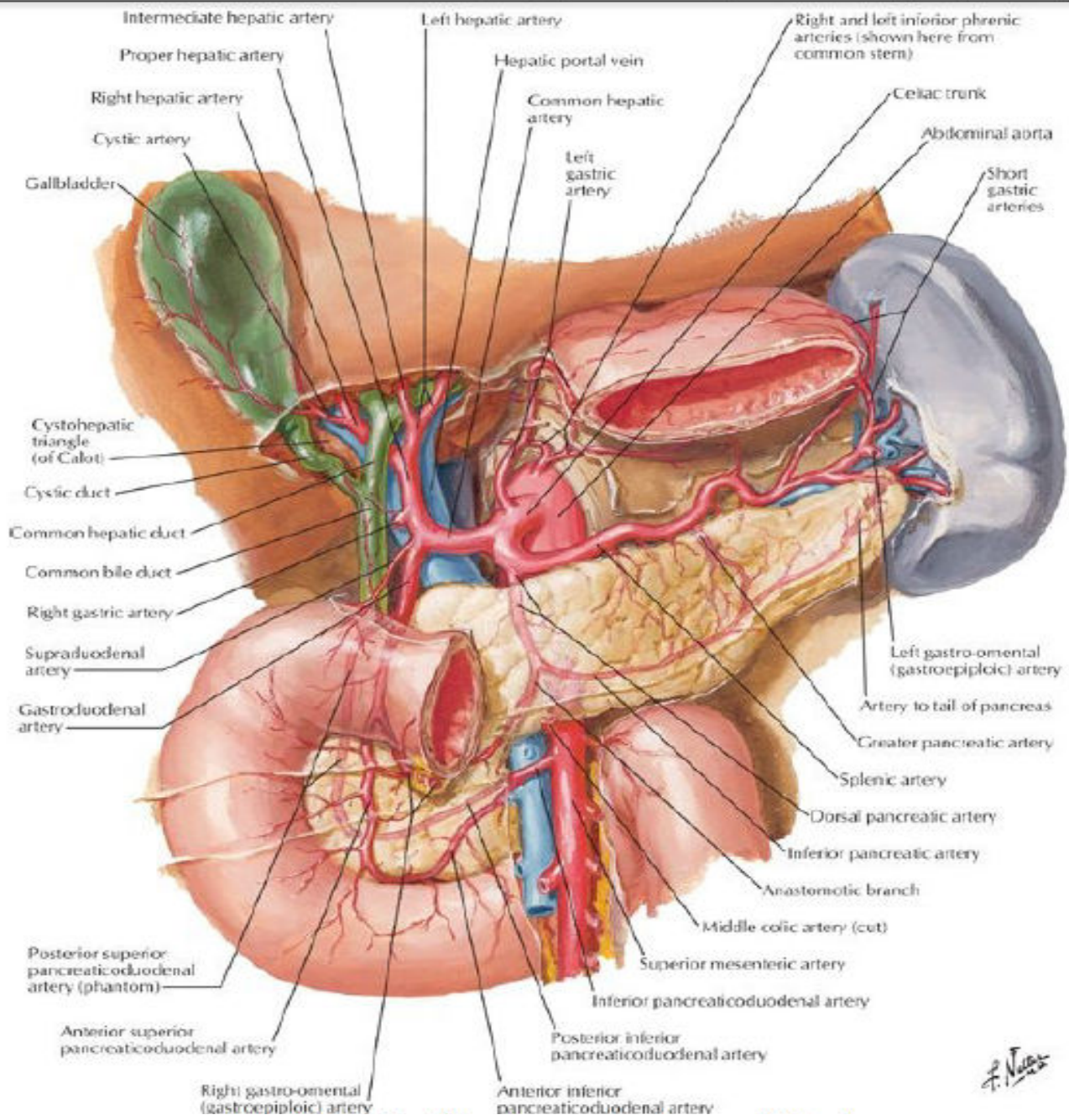






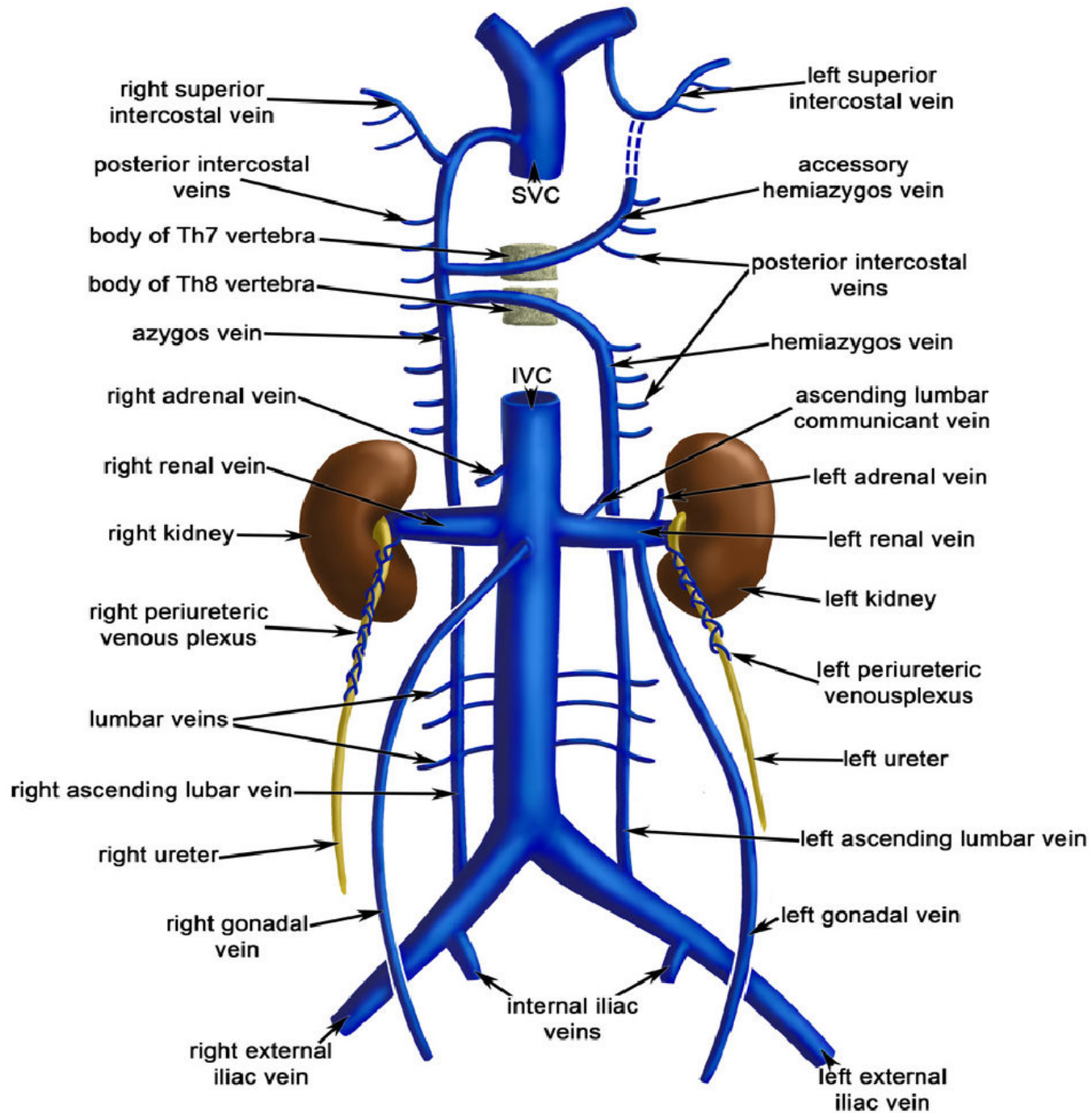


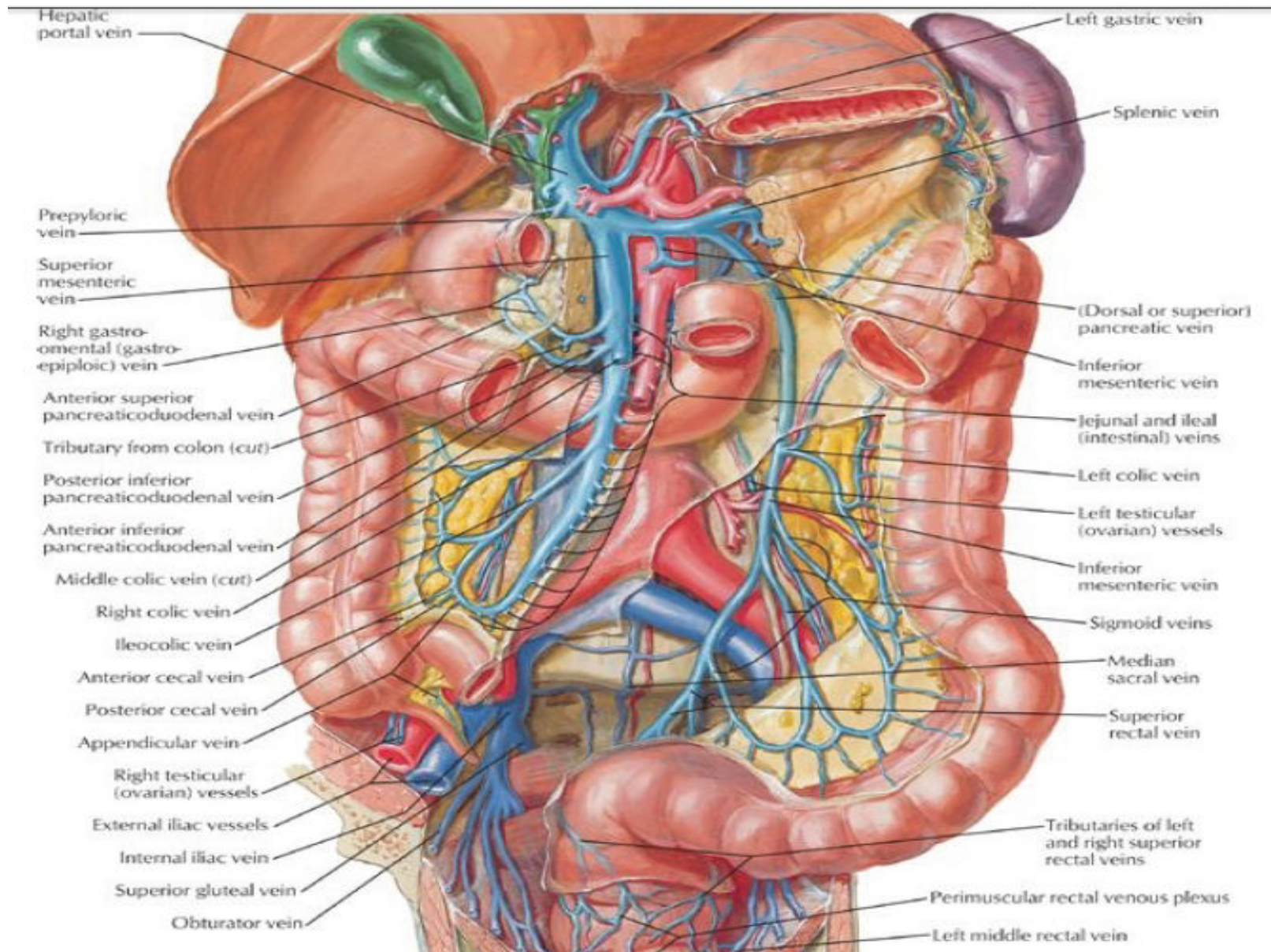


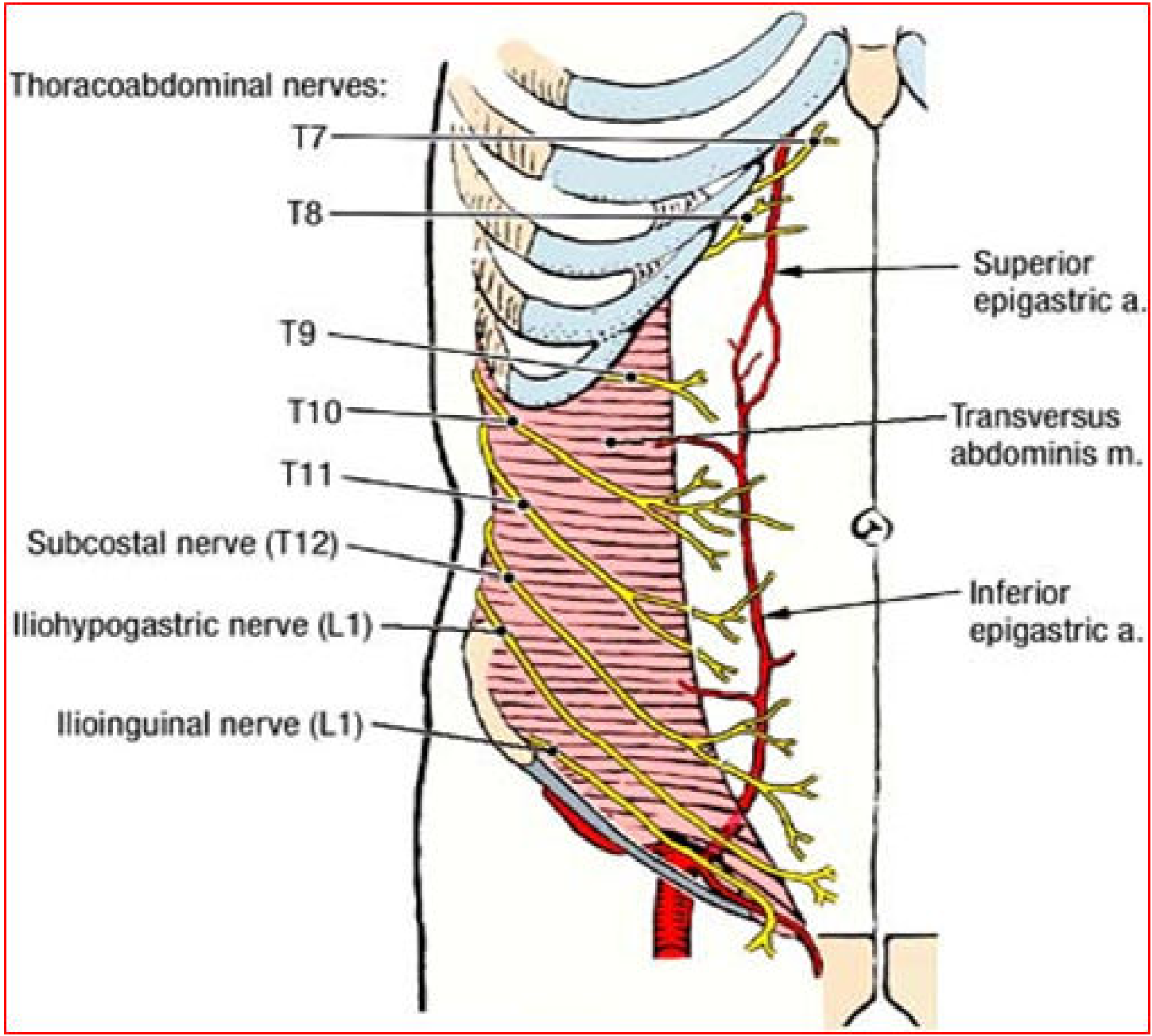


*F. Netter*









**Name the structure located inside the middle mediastinum:**

- A. Ascending aorta
- B. Aortic arch
- C. Brachiocephalic artery
- D. Left common carotid artery
- E. Right common carotid artery



## What is the right posterior relation of the Arch of the aorta ?

- A. superficial cardiac plexus
- B. Left common carotid
- C. Left vagus nerve
- D. Subclavian artery
- E. Left recurrent laryngeal nerve



**THANK YOU**

